

# Biomechanics of The Spine

Richard A. Banton, DPT, OCS, CMPT, ATC

**M**ovement in the human body occurs at joint surfaces; movement occurs with bones; movement of muscles moves the bones; coordinated movements of limbs create strong purposeful movements in a pain-free person. Notice that the list begins with movement at a joint. It is at this anatomical level that the central nervous system interprets and coordinates a neuro-musculoskeletal response into a functional movement. Therefore, logic would tell us that to improve function, one must ensure that articular motion is functionally optimal.

*“If there is a single word that encapsulates all that physical therapy stands for, it is movement.”<sup>1</sup>*

In physical therapy school, it is tradition to study anatomy and biomechanics in a regional manner. For example, the lumbar spine is studied separate from the sacrum which is, in turn, studied separate from the hip. While it is important to understand regionally specific anatomy, successful outcomes in physical therapy are only achieved by understanding how the regions of the body work together. This article summarizes a few biomechanical principles of the spine as viewed from the perspective of manual physical therapists.

## Movements and Motions of the Spine

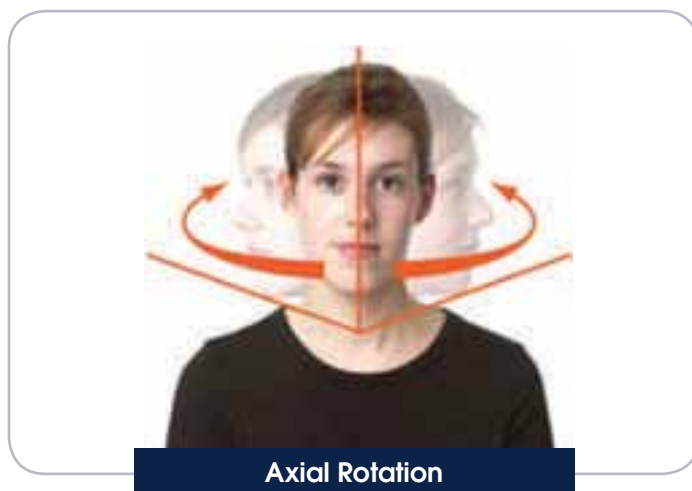
*Rotational movements* are movements of the vertebra around an axis. All rotations produce a change in the orientation of the vertebra.<sup>2</sup>

*Translational movements* are movements of the whole vertebra by the same amount in a given direction. There is no change in the orientation of the vertebra. Translation is the “gliding” of the vertebra; it rarely occurs by itself, but often accompanies other movements.


The movements of each spinal segment are limited by anatomical structures such as ligaments, intervertebral discs, and facets. Specifically, anatomical structures



Flexion/Extension



Axial Rotation



Lateral Bending

**Figure 1.** Flexion/Extension (bending), axial rotation(torsion), and lateral bending (side bending). Picture courtesy of Medtronic, Inc.

cause the *coupling of motions* of the spine, that is, movements occur simultaneously. Flexion, extension, translation, axial rotation, and lateral bending are physiologically coupled. The exact pattern of coupling depends on the regional variations of anatomical structures.

In the cervical and upper thoracic spine, side bending is coupled with axial rotation in the same direction. In the lumbar spine, lateral bending is coupled with axial rotation in the opposite direction. In the

middle and lower thoracic spine, the coupling pattern is inconsistent.<sup>1</sup> However, the pattern of coupling will change depending on which movement is initiated first. In the lumbar spine, lateral bending will be coupled with axial rotation in the same direction if lateral bending is the first movement. Conversely, if axial rotation is the first movement, it will be coupled with lateral bending in the opposite direction. The terms *latexion* and *rotexion* have been applied to these coupling patterns (Figure 3 and 4).

There has been relatively more interest in *latexion* and *rotexion* recently, largely because abnormal coupling patterns have been linked to instabilities. Changes in coupling patterns have also been observed adjacent to spinal fusions. Finally, these particular coupling patterns may have relevance in the basic biomechanics of the different regions of the spine and understanding them may lead to new discoveries in the evaluation and treatment of scoliosis.

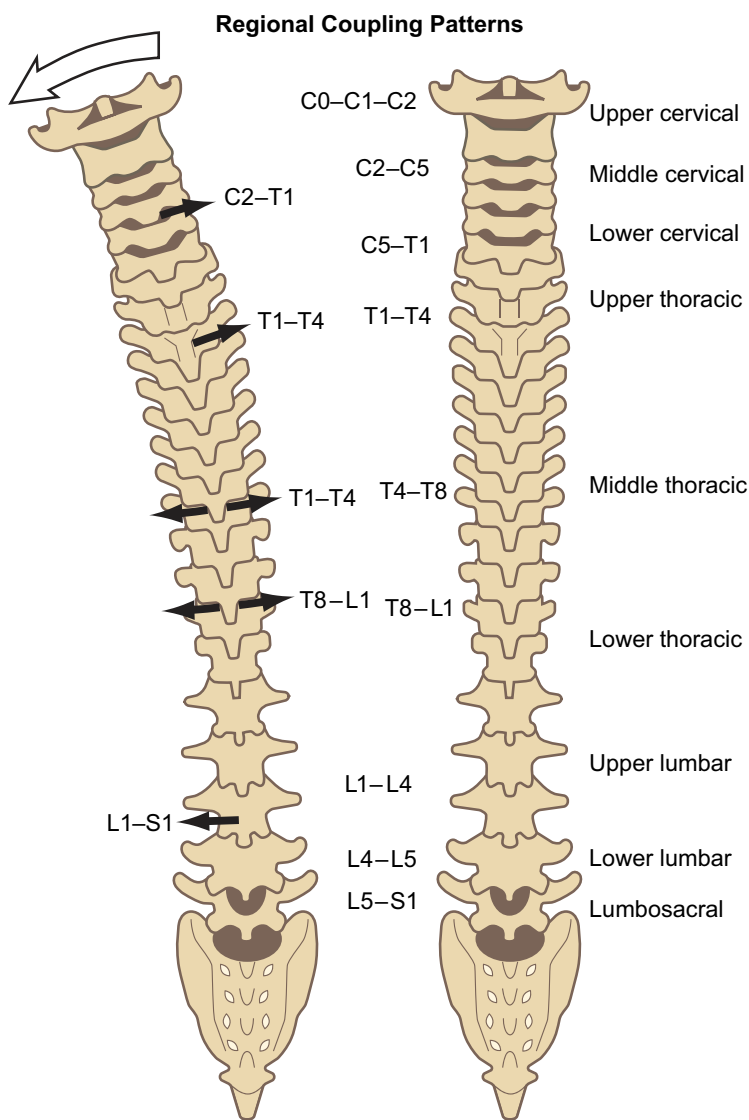
### The Cervical Spine

Because of kinematic and clinical uniqueness, the cervical spine is divided up into the occipital-atlanto-axial complex (C0-C1-C2), the middle cervical spine (C2-C5), and the lower cervical spine (C5-T1).<sup>3</sup>

The occipital atlanto-axial region is so unique and complex that controversy exists regarding the exact biomechanics of the region. About 60% of the entire cervical spine axial rotation occurs from C0-C2 and about 40% occurs from below.<sup>1</sup> The uniqueness of this region is primarily related to the articular surfaces of the first two cervical vertebrae. They are unlike any other vertebrae in the human body because they are both convex articulating surfaces. This unique geometric shape facilitates significant motion of the human head.<sup>1</sup> While other vertebral segments acquire their stability from vertebral discs, the C1-C2 complex achieves stability through dense ligamentous structures (i.e., alar ligaments and transverse ligaments.)

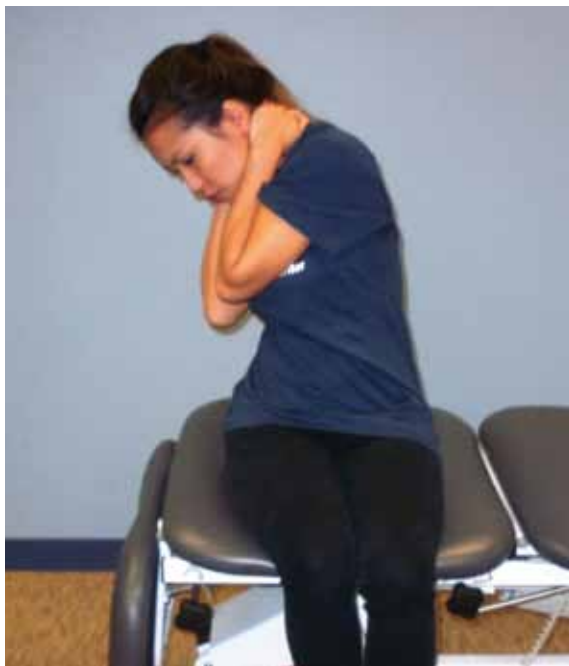### The Occipital-Atlanto-Axial Complex (Upper Cervical Spine)

Most controversy regarding movement of the spine exists in the upper cervical spine. The unique convex on convex orientation of the C1-C2 complex



**Figure 2.** Regional coupling patterns of lateral bending and axial rotation. Image modified and adapted from White, A.A. and M.M. Panjabi (1990). *Clinical Biomechanics of the Spine*. Philadelphia, PA, Lippincott.

## Spines in Motion: The Biomechanics of the Spine

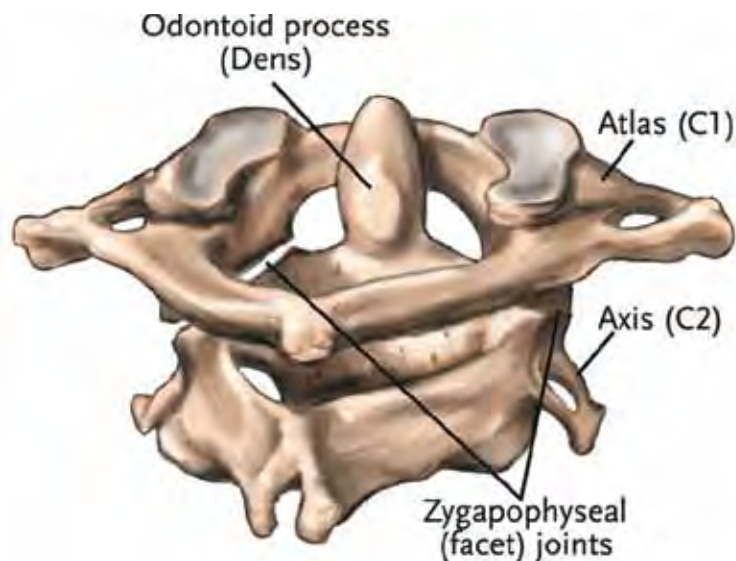


**Figure 3.** Rotexion: rotation to the right coupled with lateral bending to the right. Image courtesy of the Virginia Therapy and Fitness Center.



**Figure 4.** Latexion: lateral bending to the right coupled with rotation to the left. Image courtesy of the Virginia Therapy and Fitness Center.

has created debate among researchers for decades. The accepted coupling pattern of this region is that rotation and sidebend of the head occurs in opposite directions. For example, when the head rotates right, C1 sidebends left. This movement pattern is made possible because of the shape of the articular condyles of C1 and C2. They are both convex in nature; however, the incline of the posterior condyle of C2 is twice as steep as the anterior surface of the condyle. Therefore, when the head rotates to the right, the right C1 condyle has farther to glide down the posterior surface of C2 than the left C1 condyle has to glide on the anterior surface of the left C2. One can easily understand how controversy exists when you consider the complex anatomy of each segment. Figure 5 demonstrates the anatomical uniqueness of the C1-C2 complex.

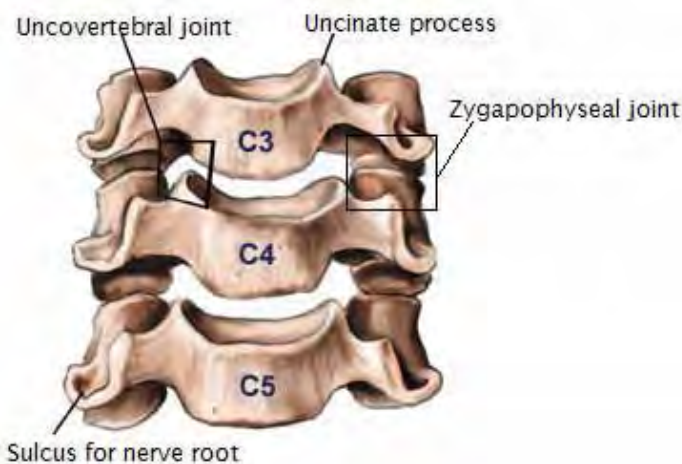


**Figure 5.** Posterosuperior view of the upper cervical vertebrae. Image courtesy of Medtronic, Inc.

The importance of coupling in the human spine is that it allows for increased mobility without sacrificing stability. When treating movement pattern restrictions of the spine, it is critical for the manual therapist to understand the unique coupling patterns of each region so that maximum mobility and stability can be achieved.

The C5-C6 interspace is generally considered to have the largest range of motion in the cervical spine,

hence the potential reason for the high incidence of cervical spondylosis (arthritis) at this segment.<sup>1</sup> As discussed earlier, the cervical spine tries to achieve maximum mobility without sacrificing stability; the uncinata processes are the structures conferring stability with mobility in the cervical spine (Figure 6). The uncinata processes become fully developed at age 18 but do not begin to develop until ages 6 to 9 years old. Considering that they help guide flexion and extension of the neck, limit lateral bending, and prevent posterior translation, one has to question the reasoning behind allowing adolescents to play tackle football or any collision sport before their necks are fully developed. Injury to the middle cervical region during adolescent years could lead to lifelong complications.<sup>1</sup>



**Figure 6.** The vertebral bodies of the subaxial cervical spine have upward projections on the lateral margins called uncinata processes. These processes articulate with the level above to form the uncovertebral joints. The zygapophyseal joints are also known as the facet joints that are comprised of the superior articular process of one vertebral body and the inferior articular process of the adjacent vertebra. *Image courtesy of Medtronic.*

Movement of the cervical spine involves a combination of uncovertebral and zygapophyseal motion (Figure 6). During neck flexion, the zygapophyseal and uncovertebral joints glide in a combined superior, lateral, and anterior direction. Reciprocally, during neck extension, the joints glide in a combined inferior, medial, and posterior direction.

## The Thoracic Spine

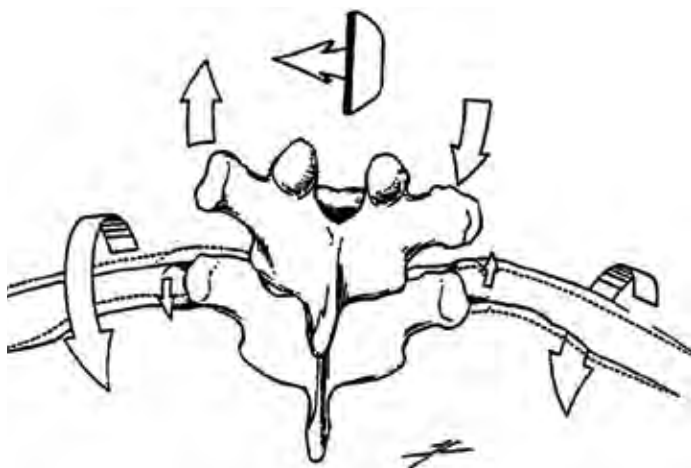
While hypermobility of the cervical spine has been associated with whiplash injuries, hypomobility of the thoracic spine has been associated with abnormal mechanical influences on both the cervical and lumbar spine.<sup>1</sup>

The unique feature of the thoracic spine is the coordinated movement of the ribcage with the vertebral segments. The addition of the ribcage increases the required compressive load necessary to cause buckling of the spine.<sup>4</sup> There is considerable motion of the spine and sternum independent of one another, allowing for motion of the spine without movement of the ribcage. During flexion of a thoracic spinal segment, there is anterior translation. This anterior translation facilitates anterior rotation of the adjacent rib. A similar motion occurs in the middle thoracic spine (T4-T7), but because of the anatomical shape of the transverse processes and the heads of the ribs, there is anterior roll of the ribs associated with a superior glide.<sup>2</sup> These minor variations in biomechanics of the thoracic spine and ribcage are critical for manual therapists to understand and analyze if their goals are to be successful in treating and restoring mobility to the thoracic spine and ribs.

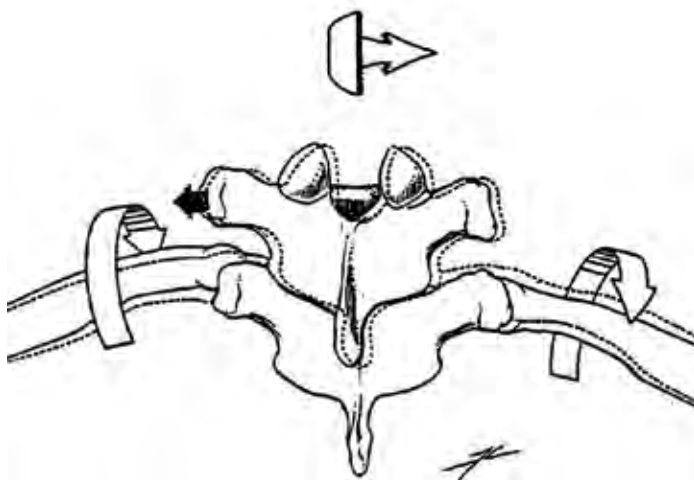
The pattern of coupling in the thoracic spine is similar to the cervical spine. Lateral bending is coupled with axial rotation in the opposite direction when lateral bending occurs as the first movement (latexion). Likewise, thoracic rotation is coupled with lateral sidebending in the same direction when rotation occurs as the first movement (rotexion). In the thoracic spine, the ribs are oriented so that they approximate when the spine sidebends. However, as further sidebending occurs, the ipsilateral ribs glides anteriorly and inferiorly along the plane of the costotransverse joint, while the contralateral rib moves superiorly and posteriorly creating rotation in the opposite direction of the sidebend (Figure 7). Conversely, rotation in the thoracic spine is accompanied by sidebending in the same direction, not because of facet orientation, but because of the ligamentous attachment of the ribs to the thoracic vertebrae (Figure 8).

Understanding the biomechanics of the thoracic spine and ribcage is important when addressing breathing and respiratory issues, chronic pain, facilitated

Spines in Motion: The Biomechanics of the Spine



**Figure 7.** Bilateral costal rotation in opposing directions drives the superior vertebra into left rotation.<sup>4</sup> Image courtesy of Lee, D. (1993). "Biomechanics of the thorax: A clinical model of in vivo function." *Journal of Manual and Manipulate Therapy* 1(1): 13-21



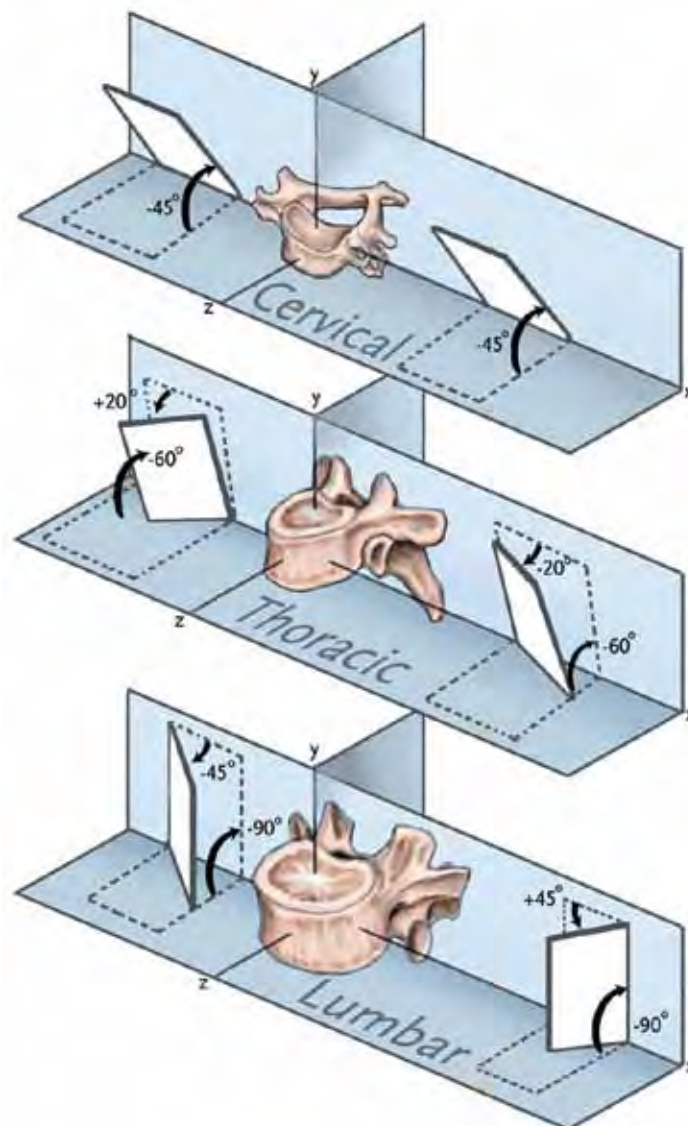
**Figure 8.** As the superior thoracic vertebra rotates to the right, it translates to the left. The right rib rotates posteriorly and the left rib rotates anteriorly as a consequence of the vertebral rotation.<sup>4</sup> Image courtesy of Lee, D. (1993). "Biomechanics of the thorax: A clinical model of in vivo function." *Journal of Manual and Manipulate Therapy* 1(1): 13-21.

segments (hypersensitive spine segments), and spinal instability. A restriction (or other dysfunction) in the spine is associated with illness of the organ(s) related to the vertebral segment (viscerosomatic reflex). Previous studies have shown that an increase in somatic dysfunction in the thoracic spine may be linked to viscerosomatic reflex phenomena. For example, Beal demonstrated that somatic dysfunction of T1-T5 was linked to cardiovascular disease.<sup>5</sup> Similarly, T6 is associated with the stomach.

During respiration, the ribs move upwards, sideways ("bucket handle") and forward ("pump handle").<sup>3</sup> This is important to understand when treating rib hypomobilities because the therapist must not only improve the ability of the rib to elevate and depress, but must also make sure the ribs can move medially and laterally.

**The Lumbar Spine**

The facet orientation of the lumbar spine facilitates more flexion and extension than rotation (Figure 9).



**Figure 9.** Facet joint orientation in the cervical, thoracic, and lumbar spine. Image courtesy of Medtronic, Inc.

In the lumbar spine, flexion and extension motions increase in range from the top to the bottom with exception of the lumbosacral joint (L5-S1). The lumbosacral joint offers more flexion/extension motion than any other lumbar segments.<sup>1</sup> With regards to lateral bending in the lumbar spine, each lumbar segment presents with approximately the same amount of movement. Likewise, axial rotation in the lumbar spine is very limited and nearly equal among each segment.

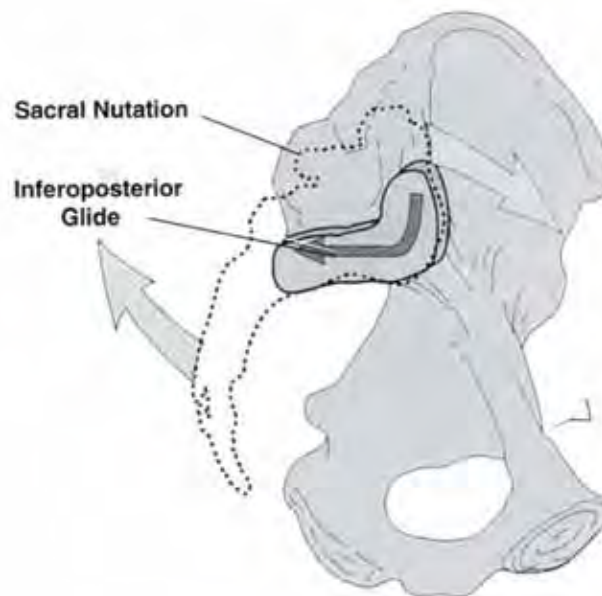
The most important aspect of lumbar biomechanics is the translation that occurs with flexion and extension.<sup>1</sup> The measure of translation in the lumbar spine is the determining factor in the diagnosis of spinal instability. Although much research is required in this region to determine more accurate measures of true spinal instability, current literature suggests that 2 mm of translation is normal for the lumbar spine.<sup>1</sup> Translation beyond 4 mm should be evaluated for clinical instability.

The unique coupling patterns associated with the lumbar spine, along with minimal mobility in the transverse plane, may directly or indirectly contribute to the higher incidence of clinical instability at the L4-L5 segment. Panjabi and colleagues have confirmed previous lumbar kinematic investigations that showed the upper lumbar segments L1-L2, L2-L3, and L3-L4 share a coupling pattern different from that of L4-L5 and L5-S1.<sup>1</sup> In the upper lumbar spine, sidebend and rotation occurs in opposite directions, while in the lower lumbar segments, sidebend and rotation occur in the same direction. In addition, Panjabi and associates discovered an interesting effect of posture on coupling patterns. In extension, the coupling motion was a flexion movement; in flexion, the coupling movement was an extension movement.<sup>1</sup> In other words, the lumbar spine always shows a tendency to straighten from either flexion or extension. The clinical significance of this finding is not yet known, but it does provide reason to further investigate the biomechanics and kinetics of the lumbar spine.

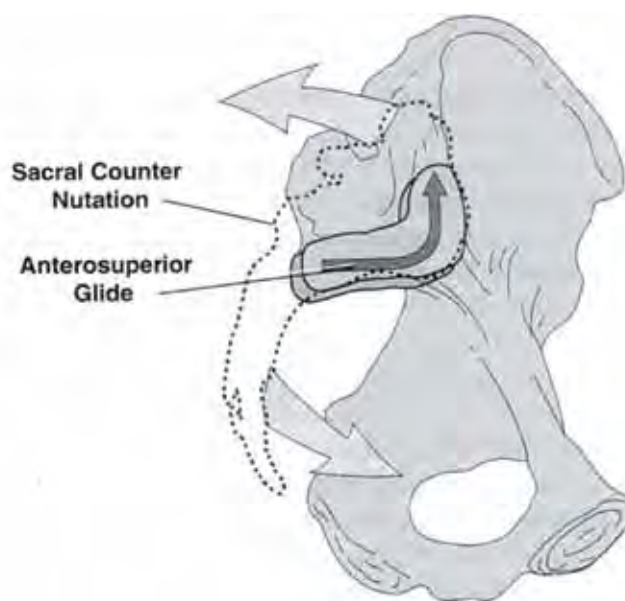
### The Sacroiliac Joint

Although mobility of the sacroiliac joint has been debated since the early 17th century, it is now accepted among all medical professionals that there is movement available in this joint.<sup>6</sup> Motion at the sacroiliac joint occurs during movement of the trunk and lower extremi-

ties. Flexion of the sacrum is called *nutation* while extension of the sacrum is termed *counternutation*. When the sacrum nutates, the sacral promontory moves anterior into the pelvis. When the sacrum counternutates, the sacral promontory moves backward (Figure 10).



**Figure 10a.** When the sacrum nutates, its articular surface glides inferoposteriorly relative to the innominate.



**Figure 10b.** When the sacrum counternutates, its articular surface glides anterosuperiorly relative to the innominate. Images courtesy of Lee, D. (1999). *The Pelvic Girdle*. Edinburgh, UK, Churchill Livingstone.

## Spines in Motion: The Biomechanics of the Spine

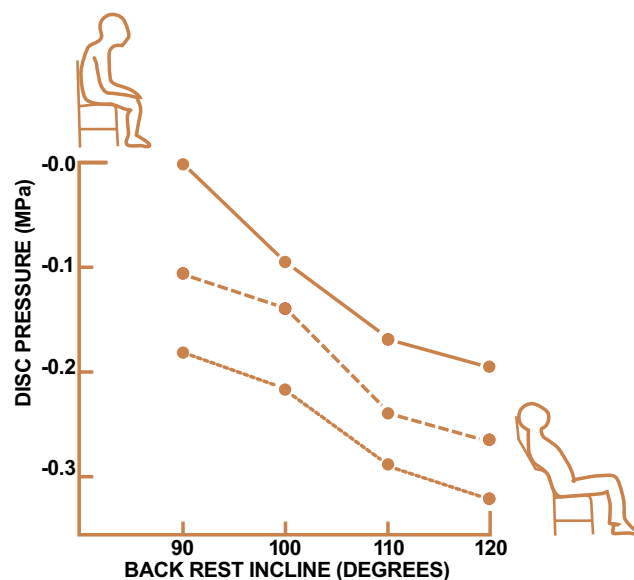
The sacroiliac joint is shaped like an “L” that has fallen backwards on its long arm. When the sacrum nutates, the sacrum glides inferiorly down the short arm of the “L” and posteriorly down the long arm of the “L” resulting in a relative anterior rotation of the pelvis. Conversely, counternutation involves the sacrum gliding anteriorly along the long arm and superiorly along the short arm.

During leg flexion, it is expected that the sacrum will nutate on the side of the flexed leg. Conversely, during leg extension, the sacrum counternutates on the side of the extended leg. Physical therapists often ask patients to flex and extend their legs during evaluation so that they can assess the mobility of the sacroiliac joint. They assess the osteokinematic of the bone or, in other words, how the bone moves in relation to another bone. When the sacrum nutates relative to the pelvis, a translation motion, or arthrokinematic occurs. Arthrokinematic refers to motion within the joint regardless of the motion of the bones.

When these movements do not occur naturally, the sacroiliac joint is diagnosed as restricted or jammed. Conversely, if these translatory motions are deemed to be excessive in nature, the sacroiliac joint is diagnosed as hypermobile. Successful results in physical therapy are achieved if the therapist and physician can concur on the state of the sacroiliac joint and appropriate treatment. Locked or jammed sacroiliac joints respond well to appropriate manipulation and mobilization, while hypermobile sacroiliac joints respond well to prolotherapy, belting, and stabilization.<sup>6</sup>

### Biomechanics and Sitting

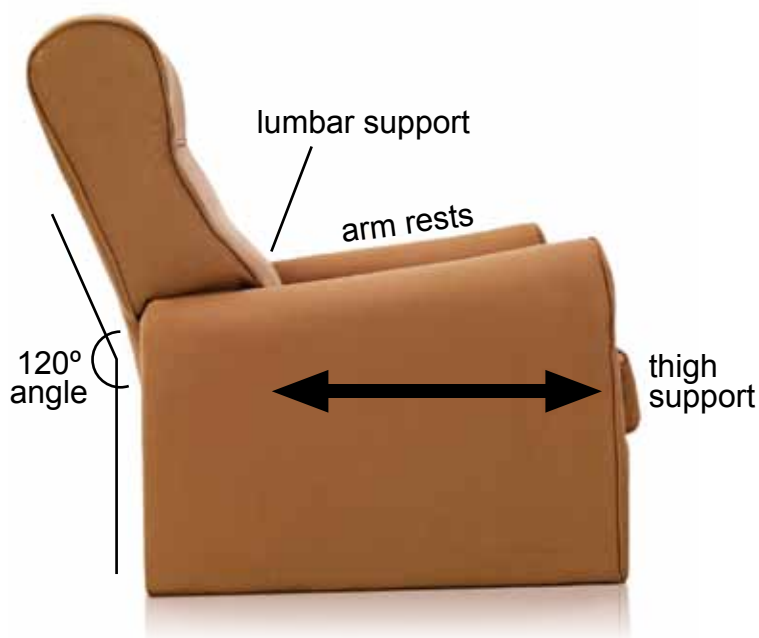
Biomechanics during sitting is of particular interest to ergonomics and the millions of people who perform their occupation while sitting. Research currently suggests that lumbar support has the greatest influence on lumbar lordosis and the inclination of the backrest had the most influence in reducing pressure within the lumbar disc.<sup>3</sup> As the inclination of the lumbar support increases, more weight is distributed on the backrest and less muscle activation is required from the erector spinae muscles of the spine (Figure 11). When the erector spinae muscles are resting there is considerably less load placed upon the vertebral discs as op-



**Figure 11.** Decrease in the intradiscal pressure with greater backrest. Image modified and adapted from White, A.A. and M.M. Panjabi (1990). *Clinical Biomechanics of the Spine*. Philadelphia, PA, Lippincott.

posed to when they are contracted.

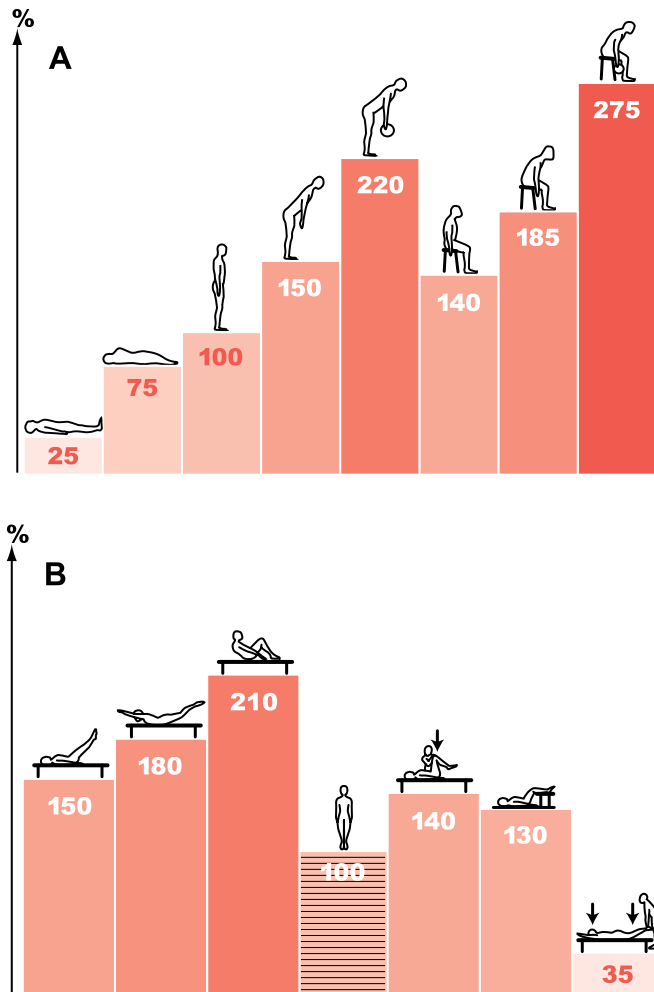
In addition to using a lumbar support, it is also recommended that using an arm rest to support the trunk can further decrease the amount of load placed upon the vertebral discs during sitting.<sup>3</sup>



**Figure 12.** Example of good seat design. Image modified and adapted from White, A.A. and M.M. Panjabi (1990). *Clinical Biomechanics of the Spine*. Philadelphia, PA, Lippincott.

### Biomechanics and Lifting

Intradiscal pressures vary with position and activities<sup>7</sup> (Figure 13).

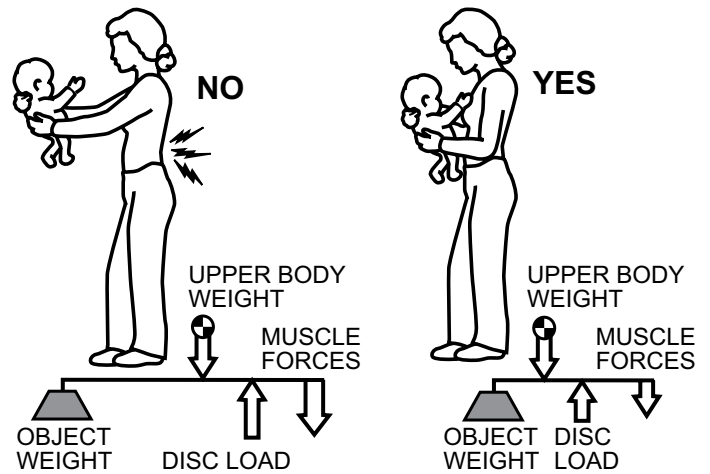


**Figure 13.** (A&B) Comparison of disc pressures in different positions and during various activities. Image modified and adapted from White, A.A. and M.M. Panjabi (1990). *Clinical Biomechanics of the Spine*. Philadelphia, PA, Lippincott.

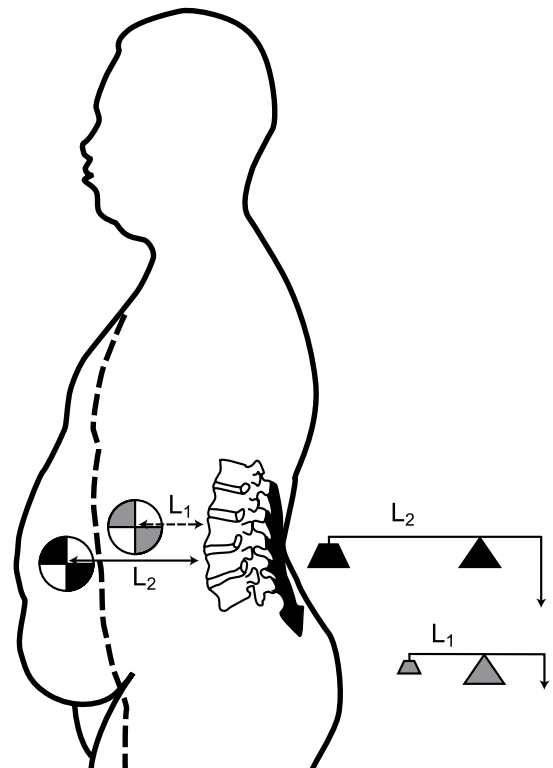
It has been demonstrated that intradiscal pressures increase when heavy weights are lifted. The heavier the weight, the larger the increase in intradiscal pressures.<sup>3</sup> Proper lifting techniques reduce the disc load (Figure 14).

Interestingly, a protruding abdomen acts as a weight carried further away from the body (Figure 15).

To avoid injury to a vertebral disc during lifting, the intradiscal pressure must be countered. Normal biomechanics and normal discs are necessary to achieve counter pressure. In a normal disc, the annular



**Figure 14.** Disc pressure is a combined result of the object weight, the upper body weight, the back muscles forces, and their respective lever arms to the disc centers. On the left, the object is farther away from the disc centers and creates greater muscle forces and disc pressures than on the right. Image modified and adapted from White, A.A. and M.M. Panjabi (1990). *Clinical Biomechanics of the Spine*. Philadelphia, PA, Lippincott.



**Figure 15.** The weight here is the adipose tissue rather than an external object. The further the abdomen protrudes, the longer the lever arm to the disc centers and the greater the disc pressures. Image modified and adapted from White, A.A. and M.M. Panjabi (1990). *Clinical Biomechanics of the Spine*. Philadelphia, PA, Lippincott.



## Spines in Motion: The Biomechanics of the Spine


fibers will be tensed by increased intra-discal pressure from the trunk flexing forward. “Normal” being the key word here, as the annular fiber orientation in a normal disc is 60 degrees from vertical as compared to a degenerative disc, whose annular fibers become more horizontal. For that reason, degenerated discs are unable to resist shear forces and therefore are more likely to be injured during lifting.

The lumbar spine achieves stability and balance during lifting because as the spine flexes forward, the accompanying counternutation of the sacrum increases tension in the thoraco-lumbar fascia. Forward flexion of the lumbar spine also triggers contraction of the pelvic floor and transversus abdominus muscles, which biomechanically tightens the thoraco-lumbar fascia. This combined action on the posterior ligamentous system acts as an anti-shearing force on the lumbar spine. If the erector spinae muscles are contracted in a flexed lumbar spine, the effect is an increased compression on the zygapophyseal joints. This would facilitate transference of load through the cortical bone of the neural arches, decreasing compression on the lumbar vertebrae, and thereby countering the intra-discal pressure.

In summary, normal biomechanical flexion is the position of power for the lumbar spine. In the absence of adequate flexion of the lumbar vertebra or in the absence of adequate ligamentous and muscular support, lifting could be hazardous to the spine.

### Conclusion

One of the primary reasons for studying spine biomechanics is to accurately identify and analyze changes that occur with pathology. For example, Panjabi and co-workers found an increase in lumbar spine translation movement in the presence of lumbar disc degeneration.<sup>3</sup> Increased translation in the lumbar spine has been linked to lower back pain.<sup>3</sup> Conversely, research has observed that up to 43% of people with low back pain have decreased or absent motion at L4-L5 and L5-S1 levels.<sup>3</sup> Some hypotheses suggest an increase in lumbar motion, while others propose a decrease in lumbar motion as a cause of low back pain. The answer is likely both. Additional research is required to learn more regarding the effects

of faulty biomechanics on the spine. Recent research has added clarity to the biomechanical model of the spine, allowing manual therapists to evaluate and treat with techniques that are more specific, thereby improving outcomes.<sup>5</sup> Further research will always be necessary to establish reliability and validity of treatment techniques and their effects on the biomechanics of the spine. 

### REFERENCES

1. Pettman E. *Manipulative Thrust Techniques. An Evidence-Based Approach*. Abbotsford, Canada: Apheria Publishing; 2006.
2. Grieve GP. *Common Vertebral Joint Problems*. Edinburgh: Churchill Livingstone; 1988.
3. White AA, Panjabi MM. *Clinical Biomechanics of the Spine*. Philadelphia, PA: Lippincot; 1990.
4. Flynn WT. *The Thoracic Spine and Rib Cage: Musculoskeletal Evaluation and Treatment*. Boston, MA: Butterworth-Heinemann; 1996.
5. Beal MC. Palpatory testing for somatic dysfunction in patients with cardiovascular disease. *J Am Osteopath Assoc*. 1983;82:822-831.
6. Lee D. *The Pelvic Girdle*. Edinburgh, UK: Churchill Livingstone; 1999.
7. Nachemson A. The load on lumbar disks in different positions of the body. *Clin Orthop Relat Res*. Mar-Apr 1966;45:107-122.



### Richard A Banton, DPT, OCS, CMPT, ATC

Richard is a certified manual physical therapist (CMPT) of the North American Institute of Manual Therapy (NAIOMT). He has served as co-clinic director for Virginia Therapy and Fitness Center since its inception in 2004. He has been practicing physical therapy since 1998, working with a variety of orthopedic, neurologic, and pediatric conditions. His degrees in sports medicine (ATC) and physical therapy (DPT) have allowed him to work with athletes from the high school and collegiate levels to professionals—Olympic athletes, the Washington Redskins, NASCAR and the LPGA.